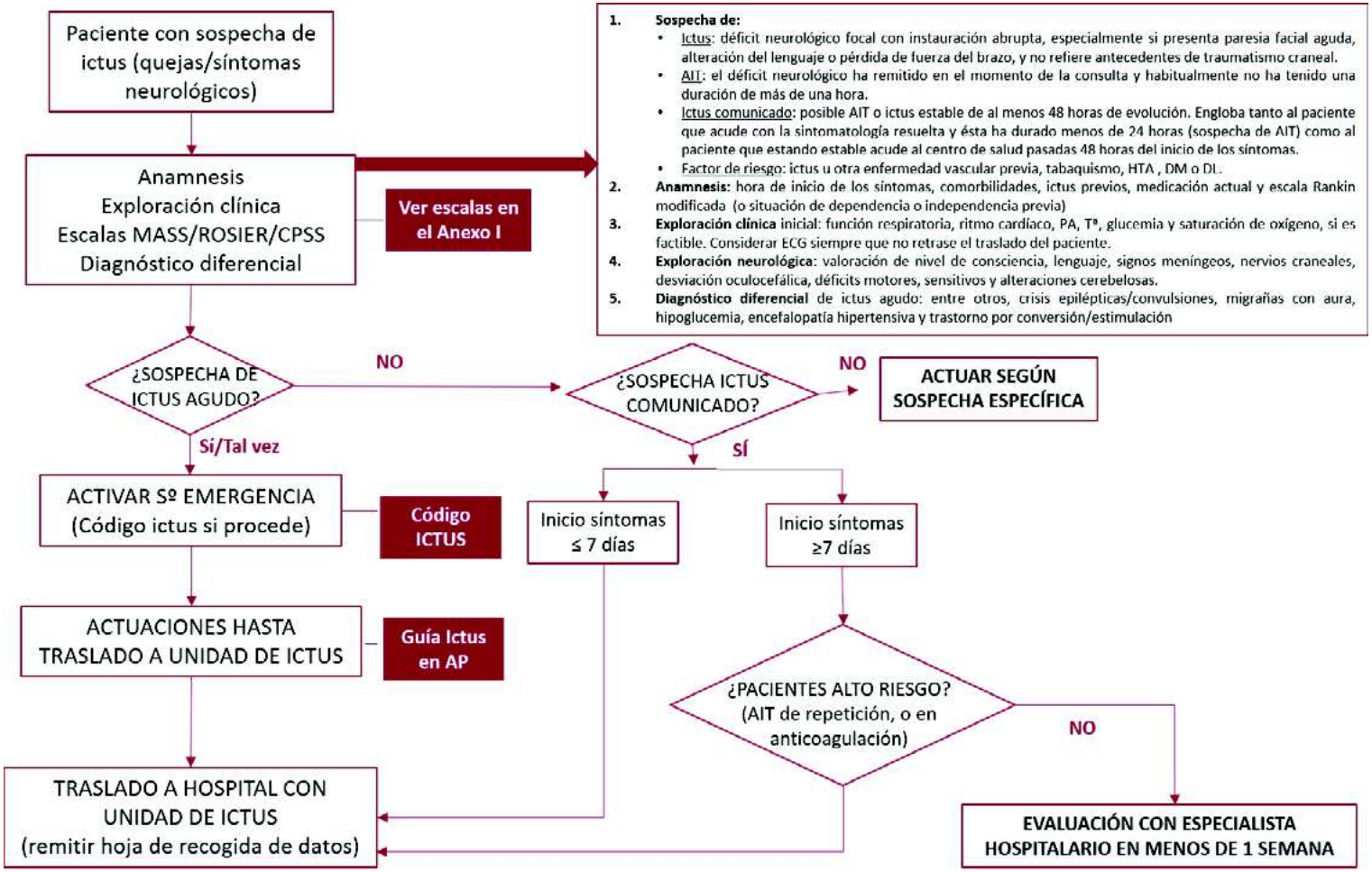Figura 1. **Estrategia a seguir ante un paciente con sospecha de ictus**